

Presented at the 2005 Chicago Supportive Oncology Conference, Chicago, Illinois

Cancer-Related Pain and Its Pharmacologic Management in the Patient With Bone Metastasis

Neal Slatkin, MD

Cancer-related pain can be defined as pain due to active cancer, cancer treatment, and/or comorbidities arising from cancer. It is vital to understand the nature of the pain experienced by cancer patients and to distinguish between its many causes and contributory factors. This can be particularly challenging in the patient with advanced cancer for whom additional antineoplastic options may be limited. Although the discussion that follows addresses many principles common to the treatment of cancer pain in all patient populations, its focus is primarily on the patient having pain due to advanced metastatic disease of bone.

Cancer Pain: An Introduction

Though pain may announce the presence of a malignancy in as many as one third of cases, it most commonly occurs in patients with locally advanced or metastatic disease. A study of palliative care outpatients indicated that pain was the most common symptom of cancer, being present in more than 80% of patients (Table 1).¹ In addition to pain, patients reported multiple other potentially debilitating symptoms, which also contributed to their overall suffering and possibly the expression of their pain.

Certain characteristics of cancer-related pain distinguish it from most other types of chronic pain:

Multifocal nature. Patients with widespread bone metastasis suffer multiple types of pain in multiple locations. To avoid treating pain as a generic rather than a specific problem, it is therefore important to identify the one or two most distress-

Abstract Cancer pain most commonly occurs in patients with locally advanced or metastatic disease. Certain characteristics of cancer-related pain, including its multifocal nature, severity, heterogeneity, progressive nature, and other special challenges, distinguish it from most other types of chronic pain. Bone metastases are the most common cause of pain in patients with malignant disease, in part due to the high frequency of axial (vertebrae, rib, and pelvis) and appendicular (femoral and humeral) fractures. Relief begins with a thorough understanding of the extent of the disease and the risks of associated complications, such as spinal cord compression. Pharmacologic approaches to pain treatment include acetaminophen, anti-inflammatory agents, opiates, and bisphosphonates. As new investigational treatments continue to develop, clinicians must continue to rely on skilled assessment techniques and an understanding of the many causes of cancer-related pain to effectively diagnose and treat pain caused by bone metastasis.

ing sites of pain and to use them to benchmark the success of analgesic therapies.

Severity. Severe pain more commonly requires aggressive treatment for its control. Moderate-to-high doses of opiates may be required to achieve pain control, and adjuvant polypharmacy frequently is necessary. Dose intensity and polypharmacy raise the risks of treatment-induced side effects, such as nausea and vomiting or sedation. Each of these symptoms may, in turn, become an additional source of distress. Constipation, probably the most common side effect of opiates, can both exacerbate pre-existing pain and cause new discomfort when not appropriately prevented or treated.

Heterogeneity. Pain may arise from somatic (eg, bone, muscle, or joint), visceral (eg, organ capsule or hollow viscus), and neuropathic pain origins and often entails combinations of these various types of pain. For instance, the patient with pain from vertebral involvement of bone metastasis may also experience radicular pain from encroachment or invasion of the nerve root and visceral pain from intractable consti-

Dr. Slatkin is Medical Director, Department of Supportive Care, Pain and Palliative Medicine, City of Hope National Medical Center, Duarte, California.

Correspondence to: Neal E. Slatkin, MD, Department of Supportive Care, Pain and Palliative Medicine, City of Hope National Medical Center, 1500 E. Duarte Road, Duarte, CA 91010; telephone: (626) 359-8111 ext 63991; fax: (626) 256-8798; e-mail: nslatkin@coh.org

J Support Oncol 2006;4(suppl 1):015-021 © 2006 Elsevier Inc. All rights reserved.

Case Report

A 53-year-old woman presented with a left breast mass, no palpable axillary adenopathy, and an otherwise normal medical history and physical examination. She does not smoke and rarely drinks alcohol. She had an excellent performance status and works full time. She underwent a tylectomy and axillary node dissection. The primary tumor was 2.2 cm², and 2 of 14 lymph nodes were positive for intraductal carcinoma. The tumor was ER-/PR- and HER2+ on fluorescent in situ hybridization. The treatment plan was radiation therapy and adjuvant chemotherapy plus trastuzumab (Herceptin). Chemotherapy consisted of doxorubicin plus cyclophosphamide for 4 cycles, followed by a taxane.

She did well with chemotherapy, but after a few

months, her energy level still had not returned to normal. She continued to work full time but did not pursue many other activities to the same degree that she did prior to the breast cancer diagnosis.

Over the past month, she noted back and shoulder pain, which gradually worsened and had not been well relieved by acetaminophen. She rated the pain as about a 7 on a scale of 1 to 10 and reported that it bothered her most of the time. Her physical examination was normal; however, x-rays of the lumbar spine and the right scapula both showed lytic bone metastases, and a bone scan also showed lesions in several ribs. A work-up did not reveal epidural metastases or any other metastatic breast cancer. She was evaluated for further anticancer treatment.

pation related to opiate treatment. Moreover, a breast cancer patient treated by our service experienced “burning” skin pain associated with en cuirass chest wall metastasis, bilateral arm pain described as “tightness” related to lymphedema and brachial plexopathy, and “aching” pain associated with widespread bone metastases. This patient also suffered from depression, anxiety, and a sense of spiritual abandonment, all of which compounded her pain. Each of these pain problems called for a different treatment approach.

Progressive nature. Cancer pain is commonly characterized by relapses, remissions, and the appearance of new sites of pain, depending on the response to antineoplastic treatment and

disease activity. We have seen a number of patients with radicular hip pain due to lumbar metastasis appear to initially benefit from radiation therapy and then surprisingly worsen. Many of these patients are then found to have an additional lytic metastasis in the pelvis or hip joint.

Special challenges. The patient with nausea and vomiting due to chemotherapy, irradiation, or peritoneal metastasis may not be able to tolerate the additional burden of visceral side effects related to opiate treatment. Some patients are ideal candidates for treatment with a nonsteroidal agent or corticosteroid but may be precluded from such treatment due to a low platelet count and the risk of gastrointestinal hemorrhage. Finally, cancer can impact the quality of life of patients adversely through other causes of suffering, including physical symptoms unrelated to pain as well as emotional and spiritual distress.

Although pain in patients with progressive cancer often is identified and treated appropriately, many patients may continue to experience cancer-related pain even as their disease is in remission or even cured. Such pain may not receive the same level of attention as does active cancer-related pain but may be no less distressing. The neuropathic effects of certain chemotherapies may continue to manifest as pain for years after treatment, as may the neuralgic complications of a thoracotomy or mastectomy. For the patient with lytic bone metastasis, fracturing may cause persistent pain due to bone instability; a biomechanical toll on the surrounding muscles,

Table 1
Common Symptoms in Palliative Care Outpatients With Cancer

Pain	82%
Easy fatigue	67%
Weakness	64%
Anorexia	64%
Weight loss	60%
Lack of energy	59%
Dry mouth	55%
Constipation	51%
Dyspnea	51%
Easy satiety	50%
Sleep problems	47%
Depression	40%

Adapted from Donnelly et al.¹

ligaments, and tendons; or permanent nerve injury from radicular compression.

Perception of Pain and Pain Ratings

As is true for all types of pain, screening for pain entails asking patients to provide an estimate of their pain on a scale of 0–10, with 10 indicating the worst possible pain. This scale is only a pain intensity screening tool and provides no information about the nature, meaning, or impact of the pain. Likewise, a high pain rating on the 0–10 scale does not elucidate specific management approaches. In acute pain, ratings on the 0–10 scale are more likely to reflect the purely nociceptive component of the patient's pain. However, in chronic pain, such as that most commonly seen with cancer, other factors (such as suffering due to multiple nociceptive, physical, emotional, psychological, and cognitive sources) can contribute substantially to the patient's perception of pain and therefore the pain rating. Depression and sleep deprivation, among other factors, may substantially lower a patient's pain tolerance.

Although aggressive pain management may appear to improve functionality and other physical signs of distress, the patient may continue to offer high pain ratings. In these instances, it is essential to look for other symptoms and issues that may impact the reported pain level rather than automatically escalate the analgesic efforts. Evidence of the substantial contribution of suffering to the experience of pain is sometimes seen in the "analgesic" benefit reported after treatment with antianxiolytics, antidepressants, and atypical antipsychotic medications.

Manifestations of Pain

In the case example, the patient with breast cancer developed pain due to bone metastases in the spine, scapula, and ribs. Bone is the third most prevalent site of remote cancer spread; metastasis to the bone is especially common in patients with breast and prostate cancers but also occurs in patients with other malignancies, such as renal, lung, thyroid, and bladder cancers.^{2,3} Bone metastases are the most common cause of pain in patients with malignant disease, in part due to the high frequency of axial (vertebrae, rib, and pelvis) and appendicular (femoral and humeral) fractures. In breast cancer, bone is the most common site of metastasis and initial relapse. Approximately one third of patients will

experience a major complication related to bone metastasis, such as fracture or hypercalcemia.⁴ Hypercalcemia of malignancy occurs in approximately 10%–15% of patients, and long bone fracture occurs in approximately 10%–20%.

In addition to the incident pain caused by pathologic fracture and microfractures, constant pain from bone metastases can be caused by stretching of the periosteum due to tumor expansion of bone; increased pressure within bone (eg, in leukemia); the release of inflammatory cytokines (eg, tumor necrosis factor-alpha, endothelin-1) and prostaglandins; neurologic compression and irritation (including spinal root compression and spinal cord compression); and muscle spasm.³ Hypercalcemia, a comorbidity of bone metastasis, may also worsen the perception of pain.

An example of constant pain is the patient with an expansile thoracic metastasis whose pain is substantially worse at night (which is relatively uncommon with nonmalignant causes of back pain). Conversely, it is not uncommon for patients to report that their pain is adequately treated when at rest but more severe with movement (incident pain), thereby limiting overall function. Pain incident to movement in patients with large joint or spinal metastasis is one of the most challenging aspects of pain management in cancer patients.

Initial Assessment

Pain relief in the patient with active cancer begins with a thorough understanding of the extent of disease and the risks of associated complica-

Case Report, continued

The patient did well following a course of palliative radiation therapy and the institution of capecitabine (Xeloda) but then exhibited evidence of progressive bone metastasis and no response to recently instituted vinorelbine. She had persistent pain, rated 7 out of 10, in multiple areas of her body but was particularly troubled by movement-induced pain in the mid-thoracic spine and right hip. Both areas are sites of previous radiotherapy. Each of these pains was rated "15 out of 10" on movement. She had no neurologic complaints, except mild, occasional unsteadiness. Magnetic resonance imaging of the brain was normal. Although she was being staged for an investigational agent, she required immediate pain relief.

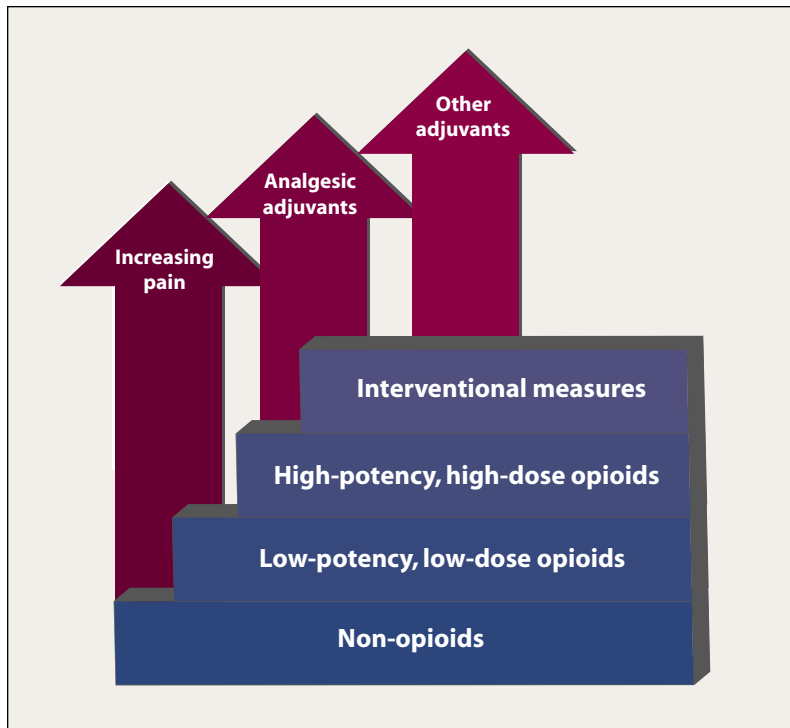


Figure 1 Cancer Pain Treatment Ladder

Cancer-Related Pain

tions, such as neurologic impairment. This is true especially for the patient with spinal metastasis, in whom the risks of paraparesis due to epidural spinal cord compression must always be considered.

To prevent significant pain, distress, and loss of function, it is important to have a high index of suspicion for this disorder and to make an early diagnosis. In addition to a routine neurologic evaluation, percussion of the spine to detect areas of pain is essential to the evaluation; such pain, especially when focal, should signal the probability of epidural metastasis, and appropriate diagnostic imaging is necessary. In addition to spinal tenderness, initial signs/symptoms of epidural compression may include increased back pain at night and subtle gait imbalance. Diagnosis is often made with magnetic resonance imaging rather than bone scan or plain radiography.

Epidural spinal cord compression may occur with virtually all solid tumors. Associated motor, sensory, and bladder/bowel problems often occur at later stages of the disorder and should not be relied upon to prompt the initial diagnostic work-up.

Figure 1 shows the basic approach to cancer pain management, in which increasing pain prompts the use of an increasingly more potent

analgesic regimen, including rational polypharmacy and (when appropriate) interventional considerations. For metastatic bone pain, external beam radiation therapy may provide near complete relief in approximately 50% of patients who have not received prior radiation therapy. This option, therefore, is often the initial therapeutic choice in patients having focal bone pain for whom there are not major contraindications to radiation therapy. Unfortunately, bone pain at previously treated sites often recurs, and although patients may have a partial response to a second course of treatment, seldom is this adequate to provide full palliation of pain.⁵ Bone-seeking, injectable radioisotopes may provide useful palliation to patients with widespread bone metastasis, especially that due to breast and prostate cancer; however, due to the common occurrence of myelosuppression, this approach is usually avoided in patients considered for additional chemotherapy.⁶

Pharmacologic Treatment of Bone Metastasis Pain

Pharmacologic approaches to pain treatment include acetaminophen, anti-inflammatory agents, opiates, and bisphosphonates.⁷

ACETAMINOPHEN

Generally regarded as the safest analgesic, acetaminophen is often undervalued in the treatment of cancer pain. Even for patients receiving high doses of continuous-release opiates, acetaminophen may make a safe and meaningful treatment addition. Acetaminophen is often combined with opiates (codeine, hydrocodone, oxycodone [Oxy-Contin]), and many patients report that the combination formulations provide better pain relief than do comparable doses of an opiate alone. Caution must be exercised when using the combination products to avoid overdosing with acetaminophen, however, due to the risk of hepatic injury resulting from the use of additional over-the-counter acetaminophen. Care is particularly warranted in patients with known hepatic injury, as the use of acetaminophen with ethanol should be avoided.

ANTI-INFLAMMATORY AGENTS

Anti-inflammatory agents, including the non-steroidal anti-inflammatory drugs (NSAIDs) and corticosteroids, are also effective in treating metastatic bone pain.⁸ For the purpose of treating cancer pain, the recent adverse publicity associ-

ated with the cyclooxygenase-2 (COX-2) inhibitors and the resultant unavailability of rofecoxib (Vioxx) and valdecoxib (Bextra) are regrettable. In our experience, these agents have been effective in the management of bone pain, and we have had few problems with serious toxicities. Advantages of the COX-2 inhibitors include a reduced risk of gastrointestinal ulceration compared with other NSAIDs, the absence of antiplatelet effects, and the convenience of once-daily dosing. Like the traditional NSAIDs, the use of these agents presents the potential for renal insufficiency, hypertension, and peripheral edema, so careful monitoring of blood-urea-nitrogen, creatinine, and blood pressure is appropriate.

Corticosteroids may control pain via a number of different mechanisms.^{9,10} They can produce both COX and phospholipase A2 inhibition, thereby curtailing the production of inflammatory prostaglandins and leukotrienes. Corticosteroids may additionally stabilize neuronal membranes, decreasing the incidence of spontaneous electrical discharges that may cause nerve pain.¹¹ Finally, the local antiedema and oncolytic effects of corticosteroids may be of particular value when pain is directly related to tumor compression or infiltration.

Corticosteroids may be highly useful in cancer pain treatment, particularly in patients with advanced cancer for whom the potential long-term adverse effects of steroid treatment may not be of primary consideration. For patients with bone metastases, for example, corticosteroids are especially useful in gaining rapid control over bone pain related to expansile tumors, such as may occur with both appendicular and vertebral metastases. This rapid activity is often beneficial to patients with epidural spinal metastasis, who can achieve a dramatic reduction in persistent pain within 24 hours of the first dose of medication.

For patients receiving palliative radiation for bone pain, it is often customary to continue corticosteroids during the early stages of treatment and then to taper them as radiotherapy nears completion. Premature tapering of corticosteroids may be associated with worsening of the underlying pain, and overly rapid tapering may cause more generalized pain related to "steroid pseudorheumatism." Other tumor-related problems for which corticosteroids often have considerable utility include headaches from intracranial hypertension as well as pain associated

with peritoneal and pleural metastases, infiltrative brachial and lumbar plexopathy, and hepatic capsular distension. Finally, corticosteroid use may produce a number of adjuvant benefits unrelated to pain control, including improvement in appetite, mood, energy levels, and control of nausea and emesis.

BISPHOSPHONATES

Bisphosphonates inhibit osteoclast-mediated bone resorption and are primarily administered to delay the evolution of skeletal events (eg, fracture) in patients having or at high risk of having osteolytic bone metastasis. In patients with bone metastasis pain, particularly when due to breast or prostate cancer, bisphosphonates, such as zoledronic acid (Zometa) and pamidronate, also may be helpful in reducing pain and the need for supplemental analgesics.^{12,13}

OPIATES

No class of medications has a longer history of pain relief or better evidence of efficacy for chronic and severe pain than do the opiates. Opiates are effective for virtually all types of cancer pain, are not associated with major organ system toxicity (unlike the NSAIDs or even acetaminophen), generally have manageable side effects, are available in multiple formulations, and may be dosed by various routes of administration.

Case Report, continued

The patient was taking two tablets of oxycodone/acetaminophen every 6 hours, which at best reduced her persistent pain to a 5 on a scale of 0–10. She had no side effects from this regimen, but the benefit lasted for only a few hours, and she began to ask for early refills.

A core principle in managing cancer pain is to treat persistent pain with long-acting (ie, controlled-release) medications and breakthrough pain with shorter-acting agents that can be dose-titrated to balance analgesia and adverse effects. In the patient in the case presentation, a long-acting opiate would be best for her persistent pain, with oxycodone/acetaminophen reserved for breakthrough pain. Currently available opiate preparations with a prolonged duration of effect include certain morphine preparations (eg, MS Contin,

Kadian), fentanyl (eg, Duragesic), oxycodone (eg, OxyContin), and methadone; investigational products include new formulations of hydromorphone and oxymorphone (Numorphan). Short-acting opiates used to treat acute or breakthrough pain include hydrocodone/acetaminophen, oxycodone/acetaminophen, hydromorphone, morphine, and transmucosal fentanyl (Actiq).

No pain-control regimen can be considered optimized unless there is also adequate control of the symptoms that may result from the analgesics themselves. To this end, diligence is needed in preventing and treating opiate-related constipation, often through the use of both stool softening and peristaltic agents. The introduction of opiates may be associated with nausea and vomiting. In addition to slow dose titration, management strategies may include the use of antiemetics and fentanyl-based products. When sedation is a problem, rotation to an alternative opiate and use of antisedative agents (eg, psychostimulants, modafinil [Provigil], and donepezil [Aricept]) may be of value.

Patient-controlled analgesia (PCA) using programmable infusion pumps provides a means of delivering both a continuous dose of opiates and also (when needed) a breakthrough dose. Although the superiority of patient-controlled opiate administration over the combination of controlled-release and short-acting opiates has not been shown in clinical studies of cancer pain, PCA may present some advantages for patients whose pain is rapidly progressive or “unstable.” Disadvantages of systemic PCA include its cost, inconvenience, and the occasional need for venous access.

Another means of PCA administration is through the use of externalized spinal catheters situated in either the epidural or intrathecal space. Little medical evidence supports the superiority of spinal administration of opiates over other optimized approaches, although some patients may experience improved pain control and fewer side effects.

OTHERS

Spasm of the surrounding musculature most commonly occurs with bone metastasis of the proximal extremities and spine and may cause pain that is poorly responsive to opiates and anti-inflammatory medications. Neuropathic pain due to compressive or infiltrative radicu-

lopathies also may occur in patients with spinal column malignancies.

Although clinical studies to guide treatment of these problems are lacking, experience suggests that medications such as baclofen, tizanidine, and lidocaine-based patches may be useful. Medications used to treat other types of neuropathic pain (eg, amitriptyline, gabapentin, pregabalin [Lyrica], or duloxetine [Cymbalta]) may be worthwhile in the cancer setting as well. Preliminary testing also shows some evidence of promise in the treatment of neuropathic pain with cannabinoid-based agents.

Case Report, continued

Vinorelbine was not effective, and the patient continued to have worsening bone tumors and liver metastasis. Persistent pain rated as 4 out of 10 (and “acceptable”) on controlled-release morphine (200 mg every 12 hours), but movement pain due to vertebral compression fractures (T-5, T-7, T-8) continued to be a problem despite the use of fentanyl oralets (1,600 µg, 6 units/d).

Conclusion

At this stage of illness, when incident pain is poorly controlled and there is evidence of refractory, progressive disease, PCA administration of morphine or hydromorphone is likely the best management choice. Should this approach fail to provide adequate analgesia, consideration might be given to vertebroplasty or surgical stabilization. In recent years, vertebroplasty and kyphoplasty have both emerged as valuable treatment approaches in refractory pain due to vertebral metastasis. Other procedural approaches for bone pain may include radiofrequency tumor lysis, alcohol ablation, cementoplasty, spinal infusion of analgesics, and hypophysectomy.¹⁴⁻¹⁶

On the horizon, a number of investigational treatments may hold promise in controlling bone metastasis pain, including selective endothelin-A receptor antagonists, antinerve growth factor antibodies, antibodies against receptor activator of nuclear factor-kappa B ligand (RANKL), and agents that block acid-sensitive ion channels.¹⁷⁻¹⁹ Until that time, skilled assessment techniques and an understanding of the many causes of cancer-related pain are needed for effective diagnosis and treatment of this all-too-prevalent complication.

References

1. Donnelly S, Walsh D. The symptoms of advanced cancer. *Semin Oncol* 1995;22(Suppl 3):67–72.
2. Hage WD, Aboulafla AJ, Aboulafla DM. Incidence, location, and diagnostic evaluation of metastatic bone disease. *Orthop Clin North Am* 2000;31:515–528.
3. Mercadante S. Malignant bone pain: pathophysiology and treatment. *Pain* 1997;69:1–18.
4. Coleman RE. Skeletal complications of malignancy. *Cancer* 1997;15(8 suppl):1588–1594.
5. Tong D, Gillick L, Hendrickson FR. The palliation of symptomatic osseous metastases: final results of the Study by the Radiation Therapy Oncology Group. *Cancer* 1982;50:893–899.
6. Farhanghi M, Holmes RA, Volkert WA, Logan KW, Singh A. Samarium-153-EDTMP: pharmacokinetic, toxicity and pain response using an escalating dose schedule in treatment of metastatic bone cancer. *J Nucl Med* 1992;33:1451–1458.
7. Berger AM, Koprowski C. Bone pain: Assessment and management. In: Berger A, Portenoy RK, Weissman DE, eds. *Principles and Practice of Supportive Oncology*. 2nd edition. Philadelphia, Pa: Lippincott Williams & Wilkins; 2002.
8. McNicol E, Strassels S, Goudas L, Lau J, Carr D. Nonsteroidal anti-inflammatory drugs, alone or combined with opioids, for cancer pain: a systematic review. *J Clin Oncol* 2004;22:1975–1992.
9. Bruera E, Roca E, Cedaro L, Carraro S, Chacon R. Action of oral methylprednisolone in terminal cancer patients: a prospective randomized double-blind study. *Cancer Treat Rep* 1985;69:751–754.
10. Posner JB. Back pain and epidural spinal cord compression. *Med Clin North Am* 1987;71:185–205.
11. Thurlimann B, de Stoutz ND. Causes and treatment of bone pain of malignant origin. *Drugs* 1996;51:383–398.
12. Berenson JR, Rosen LS, Howell A, et al. Zoledronic acid reduces skeletal-related events in patients with osteolytic metastases. *Cancer* 2001;91:1191–1200.
13. Lipton A, Theriault RL, Hortobagyi GN, et al. Pamidronate prevents skeletal complications and is effective palliative treatment in women with breast carcinoma and osteolytic bone metastases: long term follow-up of two randomized, placebo-controlled trials. *Cancer* 2000;88:1082–1090.
14. Callstrom MR, Charboneau JW, Goetz MP, et al. Painful metastases involving bone: feasibility of percutaneous CT- and US-guided radio-frequency ablation. *Radiology* 2002;224:87–97.
15. Halpin RJ, Bendok BR, Liu JC. Minimally invasive treatments for spinal metastases: vertebroplasty, kyphoplasty, and radiofrequency ablation. *J Support Oncol* 2004;2:339–351; discussion 352–355.
16. LaRossa JT, Strong MS, Melby JC. Endocrinologically incomplete transethmoidal trans-sphenoidal hypophysectomy with relief of bone pain in breast cancer. *N Engl J Med* 1978;298:1332–1335.
17. Clohisy DR, Mantyh PW. Bone cancer pain. *Cancer* 2003;97(3 suppl):866–873.
18. Lipton A. Pathophysiology of bone metastases: how this knowledge may lead to therapeutic intervention. *J Support Oncol* 2004;2:205–220.
19. Roodman GD. Mechanisms of bone metastasis. *N Engl J Med* 2004;350:1655–1664.

N O T E S